OPEN ACCESS

Clinics Oncology

Case Report

Article Information

Received date: Aug 12, 2019
Accepted date: Aug 25, 2019
Published date: Aug 26, 2019

***Corresponding author**

Chrisostomos Sofoudis, Department of Obstetrics and Gynecology, Konstandopoulio General Hospital Athens, Ippokratous 209, 11472, Athens, Greece, Email: Chrisostomos.sofoudis@gmail.com

Copyright

© 2019 Sofoudis C. This is an open-access article distributed under the terms of the Creative Commons Attribution License, which permits unrestricted use, distribution, and reproduction in any medium, provided the original author and source are credited.

Thanatophoric Dwarfism Complicating Pregnancy - An Extremely Rare Case

Papamargaritis Eythimios[1], Moschopoulou Sevasti[1], Theodoropoulos Periklis[2] and Sofoudis Chrisostomos[1*]

[1]Department of Obstetrics and Gynecology, Konstandopoulio General Hospital Athens, Greece
[2]Fetal Medicine Specialist, Greece

Abstract

Thanatophoric Dwarfism represents a lethal form of skeletal dysplasia, characterized by achondrogenesis. It is also referred to as lethal short limb dwarfism and exerts distinct clinical, radiographic and genetic features in relation to typical achondroplasia. Being extremely rare it affects 1:20,000 to 1:40,000 births. Still Thanatophoric Dwarfism is considered to be the commonest form amongst lethal achondroplasias.

Affected patients present with clinical features of underdeveloped skeleton combined with short limb dwarfism and as the name of the disease suggests, it is most commonly incompatible with life.

This case report refers to the rare case of a 28-year-old pregnant woman, whose embryo was found to exert ultra-sonographic features of Thanatophoric Dwarfism in the nuchal translucency scan. Following genetic counseling, treatment of choice consisted termination of pregnancy. Final diagnosis (Type 1 Thanatophoric Dwarfism) was established by postmortem histologic findings.

Keywords: Pregnancy; Skeletal dysplasia; Thanatophoric dwarfism

Introduction

Thanatophoric Dwarfism apart from being the commonest form of lethal achondroplasias, it is also considered to be the most lethal. It is classified into two subtypes based on the clinical features of affected patients [1]. Patients suffering from Type 1 Thanatophoric Dwarfism present with flattened spinal bones, curved thigh bones and short thoracic ribs. The most representative clinical feature of Type 2 Thanatophoric Dwarfism is the "Cloverleaf Shaped" skull. Type 1 Thanatophoric Dwarfism is by far the commonest clinical form of the disease. Being extremely rare, it is considered to be the result of an autosomal dominant mutation of the fibroblast growth factor receptor 3 genes. Diagnosis of Thanatophoric Dwarfism is established through imaging findings, according to the ultrasound findings of prenatal testing. The diagnosis is most commonly established over the second trimester of pregnancy. Final diagnosis requires histologic evaluation.

However, typical clinical disease features can be depicted during first trimester scan as well. Its prognosis is extremely poor with most embryos dying in utero.

Therefore, once diagnosis is established, very detailed genetic counseling is required aiming at allowing the parents of the affected embryo to take an informed decision concerning the termination of pregnancy or not. We hereby present the rare case of a young pregnant woman, diagnosed by Thanatophoric Dwarfism during nuchal translucency ultrasound scan at 13 weeks of pregnancy. The aim of our study reflects

Copyright © Sofoudis C

Figure 1: Fetal Thanatophoric Dwarfism

proper diagnosis, counseling and treatment of choice in such rare cases.

Case Presentation

We present a 28-year-old (gravida 5, para 2) pregnant woman admitted at our antenatal clinic during her 6th week of gestation. Reaching the 8th week, positive fetal heart beat was diagnosed. Next step, a specialized prenatal diagnosis center in order to evaluate the range of Nuchal Translucency (NT) Ultrasound Scan between the 11th and 13+6th week of gestation. Maximal diameter of NT up to 2, 1mm inside normal range. Nasal bone was present. Unfortunately, through ultra-sonographic evaluation, a fetal congenital dysplasia of the spine was diagnosed.

Specifically, a diagnosis of lumbar scoliosis accompanied by possible absence of lumbar vertebrae was made. The diameter of CRL was found shorter in diameter than expected, while fetal limbs and head appeared to be normal in growth. Fetal biometry revealed Biparietal Diameter definition (BPD) of 30.0mm, Head Circumference (HC) of 102.1mm, and Femur Length (FL) of 10mm. Ultra sonographic gestational age was diagnosed with 2 weeks' diversion than similar measured according to last menstrual period. No other abnormalities were revealed in the scan. Following these depicted imaging findings, was established the diagnosis of severe achondroplasia consistent with Type 1 Thanatophoric Dwarfism.

Both woman and her partner did not suffer from any medical conditions either congenital or acquired. They did not take any medication or any recreational agents before or during pregnancy. Equally, they did not have any family history of congenital disorders or skeletal dysplasia. We must mention a history of a first trimester spontaneous abortion followed by uncomplicated pregnancies.

The children were both healthy with no congenital defects. The woman was neither a smoker nor an alcohol drinker before or during her pregnancy. Furthermore, she was not exposed to any teratogenic medication or harmful environmental factors such as radiation during her pregnancy. Following ultrasound imaging findings, the couple had excessive genetic counseling, regarding the prognosis and implications of the condition for the well-being of their fetus.

The couple elected to go on with medical termination of pregnancy. Given the advanced gestational age of 16 weeks at the time the decision was made, the abortion was induced using analogues of synthetic prostaglandin, followed by dilatation and curettage. Histologic evaluation revealed a characteristic depiction of the mentioned fetal skeletal dysplasia.

The fetus was presented with Enlarged Thorax, Normal Skull and Extremities in size, but Small Body Through (Figure 1). X-ray depiction confirmed all preoperative imaging findings (Figure 2).

The pregnancy was successfully terminated and the patient was discharged from the hospital in good clinical condition the following day.

Discussion

First report of Thanatophoric Dwarfism dates back in 1967, when Maroteaux et al., published the first scientific report of the disease [2]. Since then very few case reports have been published due the rarity of this disastrous diagnosis. According current bibliography, incidence varies between 1 in 20,000 to 1 in 50,000 [3]. It is a sporadic rather than inherited disease since affected individuals do not survive to pass it on to next generations. The rarity of the disease makes the presentation of this case important.

Thanatophoric Dwarfism represents a congenital disease, caused by de novo autosomal dominant mutations in the Fibroblast Growth Factor Receptor 3 gene, abbreviated as FGFR3 [4]. FGFR3 gene is located on chromosome 4p16.3. Mutations in FGFR3 gene lead to abnormal long bone development. Normally fibroblast growth factors bind to the receptor of the fgfr3 gene, thus activating a signal pathway that regulates endochondral ossification [5].

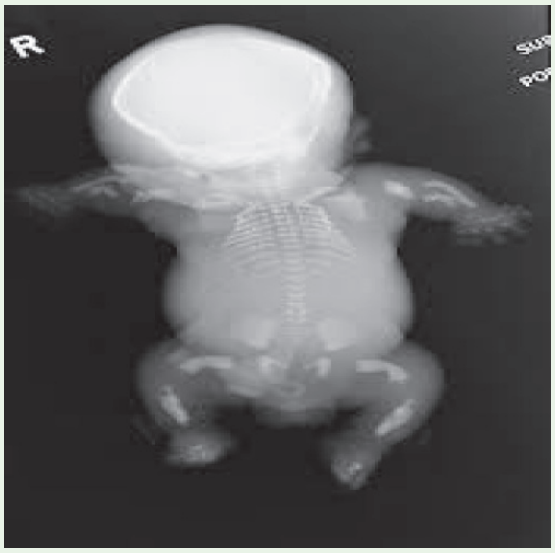

Figure 2: X-ray depiction of Thanatophoric Dwarfism

Citation: Eythimios P, Sevasti M, Periklis T and Chrisostomos S. Thanatophoric Dwarfism Complicating Pregnancy - An Extremely Rare Case. Clin Oncol. 2019; 2(3): 1015.

Copyright © Sofoudis C

Next step, combined stimulation of cell maturation and differentiation and inhibition of cell division [6]. Nowadays, the mutated gene receptor is activated in the absence of growth factors. Several other mechanisms have been proposed but are under investigation. Patients affected by Type 1 Thanatophoric Dwarfism, consist 80% of cases, typically present with the characteristically "telephone receiver" shaped femur [4]. Their thorax appears small, causing the abdomen to protrude in relation to the chest. Type 1 Thanatophoric Dwarfs have a normally shaped skull in contrast with those affected by Type 2 Thanatophoric Dwarfism who present with a "cloverleaf" shaped skull.

Based on clinical features the disease can be differentiated from other forms of achondroplasia or achondrogenesis. All affected patients tend to have ribs shorter than normal, large anterior fontanel, macrocephaly, and severe platyspondyly, bradydactyly, along with markedly short and bowed long bones[5]. Affected patients also present with frontal bossing, flat face and low nasal bridge. The diagnosis of the disease is most commonly established during prenatal ultrasound testing. An early first trimester diagnosis is feasible, especially with the introduction of three-dimensional ultrasonography in the clinical routine.

In second trimester ultrasound the phenotypic features can be even more clearly seen. However, an early diagnosis is always most preferable, especially for couples, who wish to terminate the pregnancy. In our case, diagnosis was established during 13th week of pregnancy, while termination was carried during the 16th week. In cases with enlarged suspicion an amniocentesis can be carried out for further confirmation. This is an option offered and discussed with the couple. The couple in our presentation preferred to proceed straight to termination of pregnancy.

The name of Thanatophoric Dwarfism correlates with its poor prognosis. The vast majority of affected embryos dies in utero, is stillborn or dies shortly after birth. Nikkel et al., reported that an affected woman died at the age of 29 [7]. However, this is the oldest known living patient. Death most commonly results from Respiratory Failure and the very few survivors have an extremely poor quality of life most commonly requiring permanent tracheostomy.

Both Fetal Ultra-sonographic findings and phenotypic features followed by therapeutic evacuation of the uterus established the diagnosis of Type 1 Thanatophoric Dwarfism.

Conclusion

The diagnosis of Thanatophoric Dwarfism is extremely rare. However, it carries an extremely high mortality rate and cannot be but a cause of extreme distress for the expecting couple. Very careful genetic counseling will enable the couple to take an informed decision.

Even though the diagnosis prenatally can only be confirmed by amniocentesis, typical phenotypic features of "Telephone Receiver" shaped femurs or "Cloverleaf" Skull, depicted in prenatal ultrasound, can reveal the range of the lesion.

References

1. Korday CS, Sharma RK, Paradhi S, Malik S. Lethal short limb dwarfism: thanatophoric dysplasia- type I. J Clin Diag Res. 2014; 8: PJ01-PJ02.
2. Maroteaux P, Lamy M, Robert JM. Thanatophoric Dwarfism. Presse Med. 1967; 75: 2519-2524.
3. Wilcox WR, Tavormina PL, Krakow D, Lachman RS, Wasmuth JJ, Thompson LM, et al. Molecular radiologic and histopathologic correlations in thanatophoric dysplasia. Am J Med Genet. 1998; 78: 274-281.
4. Manisha S, Jyoti, Rekha J, Devendra. Thanatophoric Dysplasia: A Case Report. J Clin Diagn Res. 2015; 9: QD01-QD03.
5. Brodie SG, Kitoh H, Lipson M, Sifry-Platt M, Wilcox WR. Thanatophoric dysplasia type 1 with syndactyly. Am J Med Genet. 1998; 80: 260-262.
6. Legeai-Mallet L, Benoist-Lasselin C, Munnich A, Bonaventure J. Over expression of FGFR3, Stat 1, Stat 5 and p21Cip1 correlates with phenotypic severity and defective differentiation in FGFR3-related chondrodysplasias. Bone. 2004; 34: 26-36.
7. Nikkel SM, Major N, King WJ. Growth and development in thanatophoric dysplasia – an update 25 years later. Clin Case Rep. 2013; 1: 75-78.

Citation: Eythimios P, Sevasti M, Periklis T and Chrisostomos S. Thanatophoric Dwarfism Complicating Pregnancy - An Extremely Rare Case. Clin Oncol. 2019; 2(3): 1015.